

Original article

Treatment of endoperio lesion caused by palatogingival groove in maxillary lateral incisor: A case report

Gunjan Agarwal¹, Anirban Chatterjee²

¹Department of Periodontics, Institute of Dental Sciences, Bareilly (U.P.), India

²Department of Periodontics, Oxford Dental College, Bangalore (Karnataka), India

*Corresponding Author: Gunjan Agarwal

Abstract

Radicular groove are one among the morphologic defects of the teeth, which have been reported as predisposing factors for periodontal disease. Palatogingival grooves may be of varied length and depth and once exposed to oral environment, bacterial plaque and calcified deposits may lodge in it. It acts as a plaque retentive area, and also impairs attachment of periodontal fibers, thus causing periodontal pocket formation. This article describe a case of male patient with palatogingival groove in maxillary lateral incisor, leading to periodontal pocket formation extending to periapical area, thus causing endoperio involvement. Tooth was well treated endodontically followed by periodontal intervention, including open flap debridement followed by regenerative procedure, along with apicectomy and restoration of palatogingival groove.

Key Words: Palatogingival grooves, plaque retentive area, pocket formation, endoperio involvement.

Introduction

Periodontal diseases comprise a group of inflammatory disease of the supporting tissues of the teeth. Plaque and calculus deposition and host response to this deposition can lead to inflammation. Factors facilitating plaque accumulation may be restorative, prosthodontic, orthodontic or anatomic factors. But whatever may be the source of plaque accumulation, the prognosis of the tooth and the probable success of periodontal therapy depends upon the entirety of correction of these etiologic factors and further prevention of plaque accumulation.

Palatogingival grooves are one among the morphologic defects of the teeth which have been reported as predisposing factors for periodontal disease.^[1] The palatogingival grooves encountered in maxillary incisors are also known as palatal gingival groove,^[1] radicular developmental anomaly,^[2] distolingual

groove.^[3] Kovacs called it as “syndesmocrono-radicular tooth”.^[4] Majority of grooves (93.8%) affect maxillary lateral incisors.^[3]

Palatogingival grooves when exposed to mouth environment lead to plaque and calculus deposition.^[3] Cleaning of these areas is difficult for the patient, causing consequent periodontal pocket formation.

Here we report a case of maxillary lateral incisor with deep palatogingival groove extending up to the root apex with severe periodontal destruction. Despite an apparently poor prognosis, tooth was successfully treated by endodontic and periodontal surgical regenerative therapy. The rationale behind treatment modalities is discussed.

Case Report

The patient was 27 years old male, who had suffered from pus discharge and mobility of upper left lateral incisor (22) for the preceding 3 months. On clinical examination, a draining sinus tract was present on the adjacent labial alveolar mucosa. There was a deep pocket (15 mm), localized at the disto-palatal line angle of the tooth, and concomitantly, a palato-radicular groove in relation to the same tooth (Fig. 1), which extended deep into the gingival sulcus. The tooth exhibited grade II mobility. Generally the patient’s oral hygiene was fair.

The underlying periodontal condition was unremarkable, and the medical history was non-contributory. An intraoral periapical radiograph revealed a periapical lesion with an advanced defect extending up to the apical third of the root (Fig. 2). Since bilateral occurrence of the palato-radicular groove is possible, same tooth on opposite side (12) was also examined, but no evidence of a palato-radicular groove was found after sulcular probing and radiography. Vitality testing of tooth 22 with an electronic pulp tester revealed a negative response, confirming the diagnosis of a nonvital pulp. Gutta-percha tracing into the sinus tract and periodontal pocket revealed the communication with the periapical area confirming chronic suppurative apical periodontitis. The bony lesion appeared to be a combined endo-perio problem.

The treatment strategy was planned that comprised supra and sub-gingival scaling with root debridement followed by root canal treatment and periodontal surgery for pocket elimination and groove repair.

After complete endodontic treatment patient was reviewed after 1 week, when periodontal surgery was performed to eliminate pocket. A full thickness mucoperiosteal flap was reflected on the labial and palatal aspect of maxillary left lateral incisor. On reflection we found an advanced circumferential angular bony defect which surrounded the distal and palatal side of the tooth and extended to the labial aspect also (Fig. 3). Granulomatous tissue was removed from the bony defect and a palatoradicular

groove which terminated on the apex of the root was noted. Following root-planing, the groove was conditioned with 10% polyacrylic acid, isolated with cotton pledgets and sealed with glass ionomer cement (Fuji I; GC Corporation, Tokyo, Japan).

Hydroxyapatite graft (Bone Medik, Meta Biomed Co., Ltd. Korea) material was mixed with saline and placed into the bony defect. The flap was stabilized and sutured with interrupted sutures. And noneugenol periodontal dressing was used to cover the wound.

The nonsteroidal anti-inflammatory drug, Ibuprofen 400mg was prescribed three times a day for 3 days and chlorhexidine mouth rinse twice a day, for a week. One week after surgery, the dressings and sutures were removed. Healing after surgery was uneventful. The patient was recalled at third, sixth, 12th month post-operatively, during which radiographs were taken for evaluation of the endodontic and periodontal status.

After 6 months, the pocket probing depth had reduced from 15 to 5 mm. There was no exudate or bleeding on probing. Intra oral periapical radiograph showed bone fill after 6 months. (Fig. 4)

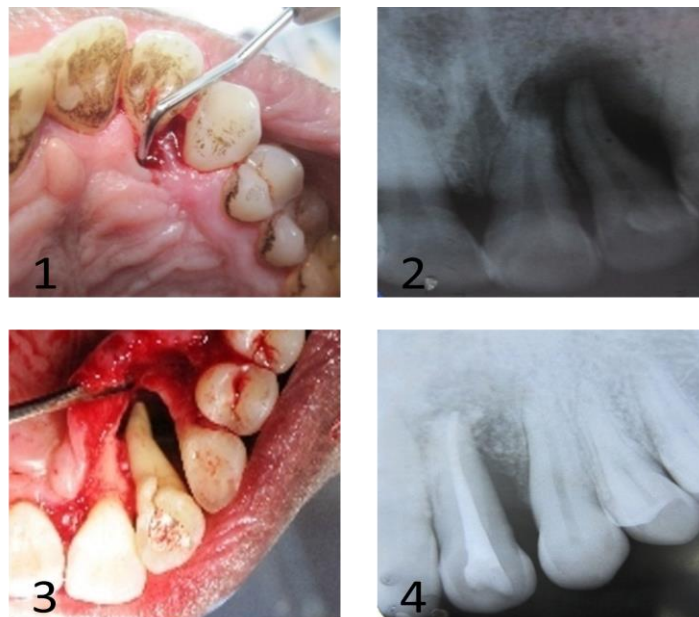


Figure 1: 15 mm pocket and a palato-radicular groove in relation to 22

Figure 2: Pre-op intraoral periapical radiograph

Figure 3: Bony defect and palato gingival groove around 22

Figure 4: Six months recall

Discussion

Palato-radicular groove is a rare developmental anomaly with a prevalence of 2.8-8.5%.^[3] The occurrence of grooves extending from cingulum to apex, as in these cases, appears to be extremely rare.^[3]

The rationale behind the selecting this treatment plan was: (1) removal or saucerization of the radicular portion of the groove to eliminate bacterial plaque and calculus and to prevent bacterial recolonization; (2) regeneration of periodontal attachment and bone and consequently improvement of the clinical conditions (reduction in pocket depth); (3) cleaning and sealing of the coronal portion of the groove to prevent bacterial recolonization.

Materials such as composite and amalgam have been used to fill the palatogingival groove.^[5,6] Although mineral trioxide aggregate sets in the presence of moisture, it might get washed off from the transgingival defect. To avoid this limitation glass ionomer cement was chosen. It also has the added advantages of having an antibacterial effect, chemical adhesion to the tooth structure, adequate seal ability,^[7,8] and promoting epithelial and connective tissue attachment.^[9]

Hydroxyapatite (HA) is one of the most bio-inert synthetic substances which is devoid of local and systemic toxicity to hard and soft tissues. Clinical evaluations have reported that the HA grafting procedure gave better results than did debridement alone in the majority of periodontal defects. Hydroxyapatite bone graft was placed to promote bone regeneration as there was an advanced circumferential bony defect.

Conclusion

This case reported the successful management of a endo-periodontal lesion precipitated and complicated by the presence of a deep palato-radicular groove whose prognosis was graded to be poor. Appraisal of the signs and the correlation of the diagnostic tests were of paramount importance in arriving at a diagnosis and appropriate management.

The key factors which may have contributed to the success of this case were effective root canal treatment with good coronal seal, periodontal attachment facilitated by elimination of the groove, placement of the bone graft into the osseous defect and periodontal maintenance.

References

1. Lee KW, Lee EC, Poon KY. Palato-gingival grooves in maxillary incisors. Br Dent J 1968;124:14-8.
2. Simon JH, Glick DH, Frank AL. Predictable endodontic and periodontal failures as a result of radicular anomalies. Oral Surg Oral Med Oral Pathol 1971;31:823-6.

3. Everett FG, Kramer GM. The distolingual groove in maxillary lateral incisor: a periodontal hazard. *J Periodontol* 1972;43:352-61.
4. Kovacs I. A systemic description of dental roots. In: Dhalberg AA, editor. *Text Book of Dental Morphology and Evolution*. Chicago, IL: University of Chicago Press, 1971. p. 223-5.
5. Friedman S, Goultshin J. The radicular palatal groove: a therapeutic modality. *Endod Dent Traumatol* 1988;4:282-6.
6. Cortellini P, Pini PG, Tonetti MS. Periodontal regeneration of human infrabony defects: I—clinical measures. *J Periodontol* 1993;64:254-60.
7. Maldonado A, Swartz ML, Phillips RW. An in vitro study of certain properties of a glass ionomer cement. *J Am Dent Assoc* 1978;96:785-91.
8. Vermeersch G, Leloup G, Delmee M, Vreven J. Antibacterial activity of glass-ionomer cements, compomers and resin composites: relationship between acidity and material setting phase. *J Oral Rehabil* 2005;32:368-74.
9. Dragoo MR. Resin-ionomer and hybrid-ionomer cements: part II, human clinical and histologic wound healing responses in specific periodontal lesions. *Int J Periodontics Restorative Dent* 1997;17:75-87.